



W/ 5896

copy 2

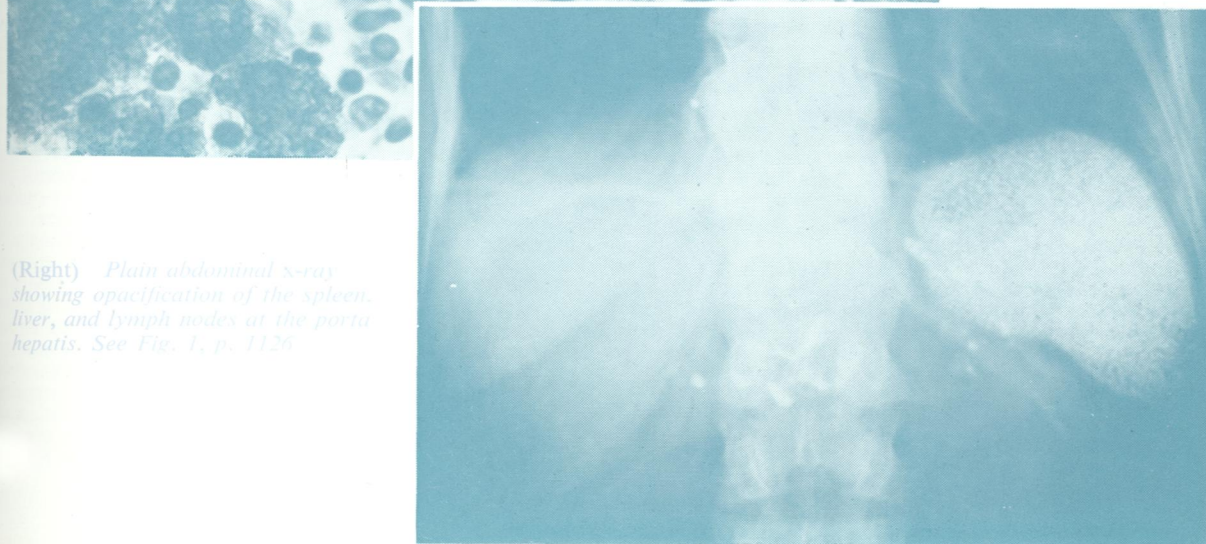
Journal of Clinical Pathology

The Journal of the Association of Clinical Pathologists

Vol. 31, No. 12, December 1978



(Left) Dense aggregates of thorotrast in the spleen (H and E \times 500) See Fig. 7, p. 1129



(Right) Plain abdominal x-ray showing opacification of the spleen, liver, and lymph nodes at the porta hepatis. See Fig. 1, p. 1126