

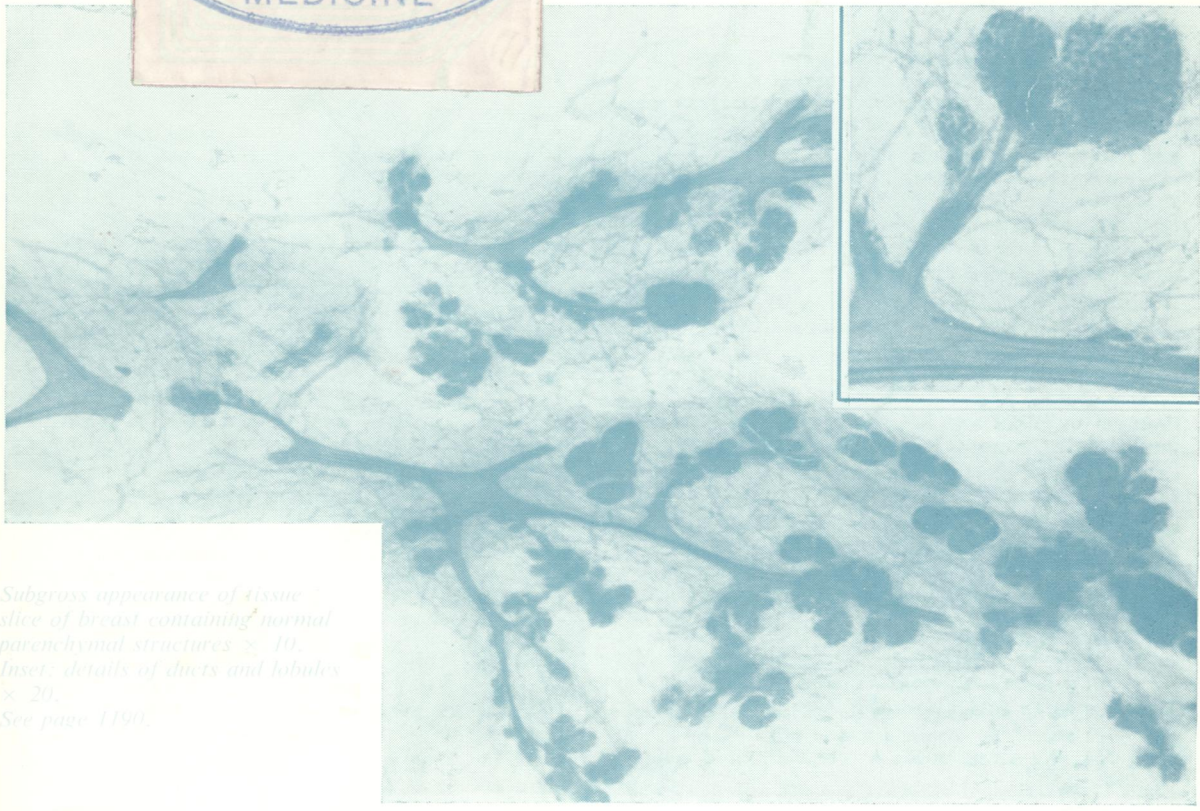

REF
W1
5896

C.2

Journal of Clinical Pathology

The Journal of the Association of Clinical Pathologists

Vol 34, No 10, October 1981



Subgross appearance of tissue slice of breast containing normal parenchymal structures $\times 10$. Inset: details of ducts and lobules $\times 20$. See page 1190.

J Clin Pathol: first published as on 1 October 1981. Downloaded from <http://jcp.bmj.com/> on May 2, 2025 by guest. Protected by copyright, including for uses related to text and data mining, AI training, and similar technologies.