

LETTER TO THE EDITOR

Gallbladder adenocarcinoma: first report in a patient with AIDS

Although a wide spectrum of AIDS-related cholangiopathy has been reported periodically, malignant tumours, commonly seen in patients with AIDS, are very rare in the gallbladder, with only handful of reports in the literature: Kaposi's sarcoma, and malignant lymphoma.^{1,2} We describe the first case of gallbladder adenocarcinoma in a patient with AIDS.

A 36-year-old man, HIV seropositive at 24, without familial history of gallbladder carcinoma, was hospitalised with right upper quadrant abdominal pain. He had chronic liver disease, hepatitis B virus-related, but no previous diagnosis of an HIV-related opportunistic infection. He was on highly active antiretroviral therapy (HAART); 2 years previously he had developed intestinal malignant non-Hodgkin lymphoma, treated by surgery and chemotherapy. The CD4+ lymphocyte count was 30/mm³ at the time of admission; HIV-1 load was 1043 copies/ml. Abdominal ultrasound showed polypoid nodules in the gallbladder. The patient underwent laparotomy with cholecystectomy, and liver biopsy. Macroscopically, the gallbladder (fig 1A) appeared distended, with two friable polyps: a 1.3 cm polyp in the middle (arrow) and a 3 cm haemorrhagic polyp on the right (arrow). There were no gallstones present. Intraoperative cholangiography showed normal biliary ducts, with a normal pancreaticobiliary ductal union.

Histopathological examination of the polyps revealed well differentiated papillary adenocarcinoma involving the muscle layer (fig 1B). Widespread involvement of the mucosa by intraepithelial neoplasia was found (fig 1C). Special stains for acid-fast organisms and fungi were negative, and no viral inclusions were found. Liver biopsy showed portal fibrosis, without cirrhosis. Subsequent segmental liver resection, and extended portal lymphadenectomy, performed after 2 weeks, showed no residual tumour. Three years later, he developed intestinal cryptosporidiosis. At the 4-year follow-up, there was no evidence of gallbladder adenocarcinoma recurrence; he was still in complete remission of intestinal lymphoma, but had started to develop resistance to anti-HIV drugs.

HIV infection is associated with an increased risk of neoplasia. Non-Hodgkin lymphoma, Kaposi sarcoma, and cervical cancer are AIDS-defining conditions. Dramatic declines in the occurrence of Kaposi sarcoma and non-Hodgkin lymphoma have been described in the HAART era, whereas other non-AIDS related malignancies have emerged, such as Hodgkin disease, acute myeloid leukaemia and lung carcinoma.³⁻⁶ Charlier *et al* have reported 5

cases of cholangiocarcinoma in HIV-infected patients with a history of cholangitis,⁷ but to our knowledge, gallbladder carcinoma in AIDS patients has never been described before.

Reported predictors of these non-AIDS related malignancies include: increasing age (older than 40 years), history of opportunistic infections, and longer duration of HIV infection.⁵ The patient described here is young, had no previous opportunistic infection before cholecystectomy, and usual predisposing factors of gallbladder adenocarcinoma (aging, lithiasis, cholangitis, porcelain gallbladder, familial history, anomalous pancreaticobiliary ductal union) were lacking.⁸ Thus the non-AIDS-related malignant nature of this carcinoma remains speculative.

The role of immunosuppression in the pathogenesis of non-AIDS-related malignancies is controversial. Increased patient survival on HAART may offer enough time for biliary carcinogenesis to occur,⁷ and immune

restoration may not control dysplastic lesions, widely present in the gallbladder mucosa in our case.

We have described the first case of gallbladder adenocarcinoma in a patient with AIDS. The strengths of our observation include long-term follow-up, spanning over a decade, leading to an early diagnosis and therapy for gallbladder carcinoma, usually known to have a very poor prognosis. This adds one more possibility to the growing list of malignancies in such patients.

N Mourra,¹ M-G Lebrette,² C Hoeffel,³ F Paye⁴

¹ Department of Pathology, Hôpital St-Antoine, Paris, France;

² Department of Radiology, Hôpital St-Antoine, Paris, France;

³ Department of Infectious Diseases, Hôpital Tenon, Paris, France;

⁴ Department of Surgery, Hôpital St-Antoine, Paris, France

Correspondence to: Dr Najat Mourra, Department of Pathology, Hôpital St-Antoine, 184, rue du faubourg St-Antoine, 75012, Paris, France; najat.mourra@sat.ap-hop-paris.fr

Competing interests: None declared.

This manuscript was accepted in abstract form at the meeting of the International Academy of Pathology, Montreal, Canada, September 2006.

Accepted 2 March 2007

J Clin Pathol 2008;**61**:688–687.

doi:10.1136/jcp.2007.048041

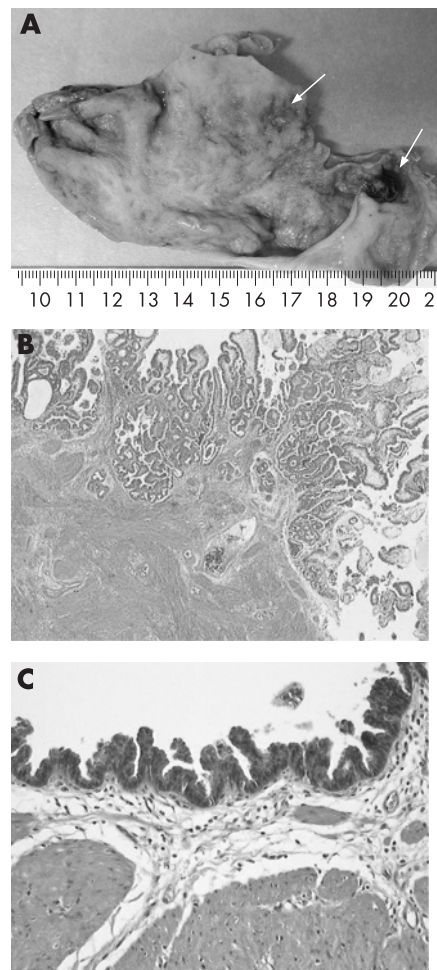


Figure 1 (A) Distended gallbladder with two polyps: 1.3 cm in the middle, and 3 cm on the right (arrows). (B) Well differentiated papillary adenocarcinoma, involving the muscle layer. H&E, $\times 25$. (C) High grade dysplasia in the non-tumoural mucosa. H&E, $\times 200$.

REFERENCES

1. Leiva JI, Etter L, Gathe J, *et al*. Surgical therapy for 101 patients with acquired immunodeficiency syndrome and symptomatic cholecystitis. *Am J Surg* 1997;**174**:414–6.
2. Kaplan LD, Kahn J, Jacobson M, *et al*. Primary bile duct lymphoma in the acquired immunodeficiency syndrome (AIDS). *Ann Intern Med* 1989;**110**:161–2.
3. Bower M, Palmieri C, Dhillon T. AIDS-related malignancies: changing epidemiology and the impact of highly active antiretroviral therapy. *Curr Opin Infect Dis* 2006;**19**:14–9.
4. Engels EA, Goedert JJ. Human immunodeficiency virus/acquired immunodeficiency syndrome and cancer: past, present, and future. *J Natl Cancer Inst* 2005;**97**:407–9.
5. Burgi A, Brodine S, Wegner S, *et al*. Incidence and risk factors for the occurrence of non-AIDS-defining cancers among human immunodeficiency virus-related individuals. *Cancer* 2005;**104**:1505–11.
6. Engels EA, Pfeiffer RM, Goedert JJ, *et al*. Trends in cancer risk among people with AIDS in the United States 1980–2002. *AIDS* 2006;**20**:1645–54.
7. Charlier C, Lecuit M, Furco A, *et al*. Cholangiocarcinoma in HIV-infected patients with a history of cholangitis. *J Acquir Immune Defic Syndr* 2005;**39**:253–4.
8. Kimura K, Ohto M, Saisho H, *et al*. Association of gallbladder carcinoma and anomalous pancreaticobiliary ductal union. *Gastroenterology* 1985;**89**:1258–65.

CORRECTION

doi:10.1136/jcp.2007.049692.corr1

There was an error in an article published in the March issue of the journal (Khan S, Alvi A, Holding S, *et al*. The clinical significance of antinucleolar antibodies. *J Clin Pathol* 2008;**61**:283–6.) On page 283 the sentence "...ribonuclease multidrug resistance protein/ribonuclease P and 10 associated proteins..." should read "...RNase MRP (Th or 7-2 RNA) and RNase P (To or 8-2 RNA)..."