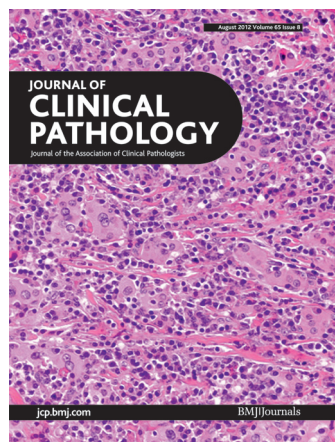

# Journal of Clinical Pathology



Cover legend: Fibrosing variant of Hashimoto thyroiditis with intense lymphoplasmacytic infiltrate within the lobules. From Dr. Vikram Deshpande et al, page 726.

Receive regular table of contents by email.  
Register using this QR code.



This article has been chosen by the Editor to be of special interest or importance and is freely available online.



Articles carrying the Unlocked Logo are freely available online under the BMJ Journals unlocked scheme.  
See <http://jcp.bmj.com/info/unlocked.dtl>

C O P E COMMITTEE ON PUBLICATION ETHICS

This journal is a member of and subscribes to the principles of the Committee on Publication Ethics  
[www.publicationethics.org.uk](http://www.publicationethics.org.uk)



equator  
network

recycle

When you have finished  
with this please recycle it

## Contents


### Reviews

- 675** Wnt signalling pathway in the serrated neoplastic pathway of the colorectum: possible roles and epigenetic regulatory mechanisms *X Fu, L Li, Y Peng*  
 EDITOR'S CHOICE
- 680** Cancers related to viral agents that have a direct role in carcinogenesis: pathological and diagnostic techniques *A Carbone, P De Paoli*  
 EDITOR'S CHOICE

### Original articles

- 687** Rsf-1 expression in rectal cancer: with special emphasis on the independent prognostic value after neoadjuvant chemoradiation *C-Y Lin, Y-F Tian, L-C Wu, L-T Chen, L-C Lin, C-H Hsing, S-W Lee, M-J Sheu, H-H Lee, Y-H Wang, Y-L Shiue, W-R Wu, H-Y Huang, H-P Hsu, C-F Li, S-H Chen*
- 693** PTEN deletion is rare but often homogeneous in gastric cancer *S Mina, B A Bohn, R Simon, A Krohn, M Reeh, D Arnold, C Bokemeyer, G Sauter, J R Izbickei, A Marx, P R Stahl*
- 699** Neuroendocrine cells associated with neuroendocrine carcinoma of the breast: nature and significance *T Kawasaki, K Mochizuki, H Yamauchi, S Inoue, T Kondo, Ni Oishi, T Nakazawa, T Yamane, Y Koshimizu, H Tsunoda, H Yagata, M Inoue, A Inoue, T Maruyama, H Fujii, R Katoh*
- 704** Mucosal large cell neuroendocrine carcinoma of the head and neck regions in Japanese patients: a distinct clinicopathological entity *K Kusafuka, M Abe, Y Iida, T Onitsuka, T Fuke, R Asano, T Kamijo, T Nakajima*
- 710** Encapsulated papillary carcinoma of the breast: a study of invasion associated markers *E A Rakha, M Tun, E Junainah, I O Ellis, A Green*
- 715** Scoring the percentage of Ki67 positive nuclei is superior to mitotic count and the mitosis marker phosphohistone H3 (PHH3) in terms of differentiating flat lesions of the bladder mucosa *S Gunia, C Kakies, A Erbersdobler, S Koch, M May*
- 721** Trends of stage, grade, histology and tumour necrosis in renal cell carcinoma in a European centre surgical series from 1984 to 2010 *M Pichler, G C Hutterer, T F Chromecki, J Jesche, K Kampel-Kettner, K Eberhard, G Hoefler, K Pummer, R Zigeuner*

## August 2012 Volume 65 Issue 8

- 725** Fibrosing variant of Hashimoto thyroiditis is an IgG4 related disease *V Deshpande, A Huck, E Ooi, J H Stone, W C Faquin, G P Nielsen*
- 729** Prostatic needle biopsies following primary high intensity focused ultrasound (HIFU) therapy for prostatic adenocarcinoma: histopathological features in tumour and non-tumour tissue *P Ryan, A Finelli, N Lawrentschuk, N Fleshner, J Sweet, C Cheung, T van der Kwast, A Evans*
- 735** Loss of SIRT1 histone deacetylase expression associates with tumour progression in colorectal adenocarcinoma *S-H Jang, K-W Min, S S Paik, K-S Jang*
- 740** Effect of thrombin receptor expression on microvessel endothelial cells, and survival by coagulation state in oesophageal squamous cell carcinoma *Y Shao, Q-Q Xu, C Li, M-Y Wu, X-Y Huang*
- 746** The molecular characterisation of unusual subcutaneous spindle cell lesion of breast *E A Takano, T-M Rogers, R J Young, M Rayoo, P Kostos, R Ferguson, I G Campbell, M Debiec-Rychter, S B Fox*
- 751** HER2/*neu* testing for anti-HER2-based therapies in patients with unresectable and/or metastatic gastric cancer *C Gómez-Martin, E Garralda, M J Echarri, A Ballesteros, A Arcediano, J L Rodríguez-Peralto, M Hidalgo, F López-Ríos*  


### Short report

- 758** Association of plasma cell subsets in the bone marrow and free light chain concentrations in the serum of monoclonal gammopathy patients  
*M J Ayliffe, J Behrens, S Stern, N Sumar*

### PostScript

- 762** Correspondence

J Clin Pathol: first published as on 1 August 2012. Downloaded from <http://jcp.bmj.com/> on April 29, 2025 by guest. Protected by copyright, including for uses related to text and data mining, AI training, and similar technologies.