









Macroscopic examination of pathology specimens: a critical reappraisal

Murali Varma ¹, Laura C Collins ², Runjan Chetty ³,
Dipti M Karamchandani ⁴, Karen Talia,⁵ John Dormer,⁶ Monika Vyas ²,
Brendan Conn,⁷ Yaileen D Guzmán-Arocho ², Adam V Jones ¹, Miranda Pring,⁸
W Glenn McCluggage ⁹

¹Department of Cellular Pathology, University Hospital of Wales, Cardiff, UK

²Department of Pathology, Beth Israel Deaconess Medical Center, Boston, Massachusetts, USA

³Deciphex/Diagnexia Pty Ltd, Dublin, Ireland

⁴Department of Pathology, The University of Texas Southwestern Medical Center, Dallas, Texas, USA

⁵Department of Pathology, Royal Children's Hospital and Royal Women's Hospital, Melbourne, Victoria, Australia

⁶Department of Cellular Pathology, University Hospitals of Leicester NHS Trust, Leicester, UK

⁷Department of Pathology, Royal Infirmary of Edinburgh, Edinburgh, UK

⁸Department of Oral and Dental Sciences, Bristol Dental School, University of Bristol, Bristol, UK

⁹Department of Pathology, Royal Group of Hospitals and Dental Hospital Health and Social Services Trust, Belfast, UK

Correspondence to

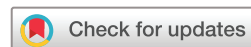Dr Murali Varma, Department of Cellular Pathology, University Hospital of Wales, Cardiff, CF14 4XW, UK; MuraliCardiff@gmail.com

Received 5 July 2023

Accepted 3 August 2023

Published Online First

22 November 2023



© Author(s) (or their employer(s)) 2024. No commercial re-use. See rights and permissions. Published by BMJ.

To cite: Varma M, Collins LC, Chetty R, et al. *J Clin Pathol* 2024;**77**:164–168.

ABSTRACT

Meticulous macroscopic examination of specimens and tissue sampling are crucial for accurate histopathology reporting. However, macroscopy has generally received less attention than microscopy and may be delegated to relatively inexperienced practitioners with limited guidance and supervision. This introductory paper in the minisymposium, *Macroscopy Under the Microscope*, focuses on issues regarding macroscopic examination and tissue sampling that have been insufficiently addressed in the published literature. It highlights the importance of specimen examination and sampling, discusses some general principles, outlines challenges and suggests potential solutions. It is critical to get macroscopy right the first time as it may not be possible to rectify errors even with expert histological assessment or to retrospectively collect missing data after the specimen retention period. Dissectors must, therefore, receive adequate guidance and supervision until they are proficient in macroscopic specimen examination. We emphasise the importance of the clinical context, optimal specimen fixation, succinct and clinically relevant macroscopic descriptions, macrophotography and judicious tissue sampling. We note that current recommendations based on the number of blocks to be submitted per maximum tumour dimension are ambiguous as the amount of tissue submitted in a cassette is not standardised and it is unclear whether 'block' refers to a tissue block or a paraffin block. Concerns around potential oversampling of 'therapeutic' specimens that could result in overdiagnosis due to detection of incidentalomas are also discussed. We hope that the issues discussed in this paper will engender debate on this clinically critical aspect of pathology practice.

INTRODUCTION

Macroscopic examination of specimens and tissue sampling are critical steps on the road to an accurate histopathology report. Therefore, it is unfortunate that macroscopy is in many ways the 'Cinderella' of histopathology, receiving far less consideration in lectures and publications than microscopy and ancillary techniques. Discussion of macroscopic issues is largely limited to the education of histopathology trainees and pathology assistants/advanced practitioners so some important issues have received insufficient attention. In sharp contrast to microscopic reporting, macroscopic examination and

specimen dissection, on which accurate reporting relies, is not uncommonly delegated to relatively inexperienced practitioners with limited guidance and supervision.

This minisymposium, *Macroscopy Under the Microscope*, focuses on issues around specimen examination that have been insufficiently addressed in the published literature. Macroscopic parameters that are critical for patient management are emphasised; those that have little clinical utility are also highlighted. In this introductory paper, we discuss some general principles and challenges, while other subspecialty focused papers in this issue of the journal discuss aspects of macroscopic examination of gastrointestinal, urological, gynaecological, breast and head/neck specimens.^{1–5}

MACROSCOPY IS PARAMOUNT

Macroscopic examination is the cornerstone of pathological assessment of a surgical specimen. If an abnormality is missed on macroscopic examination and therefore not sampled, it cannot be identified even by expert histological examination. The missed 'abnormality' could be an entire tumour or areas within a tumour showing adverse prognostic features such as sarcomatoid change in a renal cell carcinoma that often has a distinctive solid fleshy grey-white appearance. Macroscopic findings may also be critical for accurate staging. The distinction of direct adrenal invasion by renal cell carcinoma (pT4) from discontinuous ipsilateral adrenal involvement (pM1) relies on astute gross examination.⁶ Microscopic examination of a section of adrenal gland involved by renal cell carcinoma may not allow this important distinction. Other examples in different organ systems are highlighted in the companion papers in this issue.^{1–5}

NARROW WINDOW OF OPPORTUNITY

Pathology specimens are retained for only a limited time after reporting so missing macroscopic data cannot be retrospectively collected after this period. Moreover, inadequate sampling for histological examination cannot be rectified once the specimen has been discarded. Even if the specimen is still available, it can be difficult to remedy suboptimal macroscopic examination on review of a previously sectioned specimen in which anatomic landmarks and orientation are disrupted or lost. For example, if the indication for a mastectomy was tumours in

separate quadrants, it is critical that these are identified before the specimen is extensively sliced. The 'Get It Right the First Time' principle is, therefore, particularly applicable to macroscopic specimen examination.

It is helpful to maintain orientation of complex specimens after cut-up to facilitate re-examination of the specimen after initial histological review. This can be done using techniques such as pinning the specimen to a cork board or wrapping the slices separately in paper towels with appropriate labelling.

IMPORTANCE OF TRAINING AND SUPERVISION

Optimal macroscopic examination and sampling require a good understanding of the elements required for a final histopathology report. Understanding the rationale behind recommendations in national and international guidelines enables pathologists to identify exceptions to general rules and adapt their approach to the requirements of a particular case. Therefore, it is crucial that trainees and pathology assistants/advanced practitioners receive adequate guidance and supervision until they are proficient in macroscopic specimen examination. In the absence of such training, the dissector may miss items of importance ('under sampling'), or 'oversample' specimens by submitting blocks of little clinical utility, which further stresses overstretched laboratory resources. Every dissector should ideally have an experienced pathologist or peer available to discuss the best approach in difficult situations.

CLINICAL CONTEXT IS CRITICAL

The dissector must be aware of all relevant clinical and imaging information prompting surgical resection before commencing specimen dissection. If a wide local excision of the breast was performed for ductal carcinoma in situ then it is desirable to correctly orientate the blocks to allow accurate reporting of extent of disease.⁷ If the specimen orientation is unclear or the macroscopic findings are discordant with the clinical information provided, the dissector should seek further information from the medical records or from the surgeon before proceeding.

OPTIMAL FIXATION IS KEY

Larger specimens should generally undergo initial slicing on receipt in the laboratory to facilitate fixation. Proper macroscopic examination requires thin slicing at 3–5 mm intervals to enable identification of small focal lesions. Such thin slicing can be difficult in unfixed or partly fixed specimens, emphasising the need for optimal fixation prior to definitive slicing. Poorly fixed tissues from some tumours such as testicular germ cell tumours and endometrial carcinomas may 'liquefy' resulting in artefactual spread of tumour that can mimic vascular invasion. Suboptimal fixation can also compromise the quality of H&E-stained slides as well as subsequent immunohistochemical and molecular testing. Optimal fixation should not be sacrificed in order to shorten turnaround time. A short delay in reporting resection specimens to optimise the collection of critical prognostic and predictive information is acceptable, particularly as adjuvant therapy often cannot be commenced until the patient has recovered from the major surgical procedure.

Prompt fixation can be particularly problematic in specimens such as the uterus and testis that have a serosal lining that impedes the permeation of formalin. To prevent underfixation, systems should be in place to ensure that such specimens are promptly transported to the pathology laboratory for optimal slicing to aid fixation. Surgeons could be educated to slice these specimens postoperatively before placing them in formalin in

scenarios where delays in macroscopic examination are likely. Some gastrointestinal tract specimens could be partially opened along the longitudinal axis without slicing through the tumour. Plugging the tumour area with formalin-soaked gauze could then facilitate tumour fixation without compromising assessment of the serosal surface or specimen margins.

SPECIMEN DESCRIPTION SHOULD BE CLINICALLY RELEVANT

Macroscopic specimen description is a crucial part of the pathology report, but it should be succinct and clinically relevant. Redundant data lengthens the pathology report and increases the risk of clinically relevant data being missed by the treating clinician. Gross reporting templates can be helpful in this regard.

It is important to keep in mind the purpose of macroscopic description. Macroscopic description provides a record of what has been excised. For example, if the cervix is not included in a hysterectomy specimen (subtotal hysterectomy) then continued cervical cancer screening may be indicated. If the presence of an adrenal gland is documented in a radical nephrectomy specimen then a subsequent ipsilateral suprarenal mass is unlikely to represent an adrenal tumour. Macroscopic description also provides information about the histologically unsampled specimen.

It is common practice to routinely record the size of specimens in three dimensions. However, many of these measurements such as uterine dimensions are generally of little clinical utility.

Specimen size is, however, important in some instances. For example, the length of small bowel excised should be documented as it could correlate with the risk of developing subsequent malabsorption. Similarly, the size of an omental specimen should be provided since this can help distinguish an omental biopsy from an infracolic omentectomy which may sometimes be important for patient management. Weight may be a simpler and more reproducible indicator of the amount of tissue removed from the patient for some specimen types.⁸

Tumour size is often an important prognostic factor and may be important in tumour staging and management recommendations but these are based on the maximum tumour dimension. The second and third tumour dimensions are generally of limited clinical utility and do not need to be routinely reported. However, these tumour dimensions could be useful in a few scenarios such as estimating the cancer burden in a postneoadjuvant therapy setting.

Correlation with the radiologically reported tumour dimensions is of paramount importance when examining the gross specimen. It is noteworthy that tumour size in predominantly cystic tumours reflects the amount of fluid rather than cellular content. It may be prudent, therefore, to record the maximum dimension of a focal solid component within a predominantly cystic tumour.

A PICTURE IS WORTH A THOUSAND WORDS

Photographs of gross specimens provide a permanent record of specimen appearances and a better illustration of the absence of a focal abnormality than random histological sampling. Photographs of the specimen surface may be necessary to illustrate critical abnormalities such as serosal mucin in an appendicectomy or capsular rupture in an ovarian tumour. A scale should be included in the photograph to allow retrospective measurements. Certain specimens that are challenging to orientate, such as vulvectomy specimens, should routinely be accompanied by a photograph or diagram indicating the location of anatomic landmarks and sections taken for histology. Routine

macrophotography of all specimens may be useful when these are dissected by inexperienced staff. Macrophotography does not necessarily need expensive equipment as this can be performed using dedicated mobile devices that are linked to the laboratory information management system. The macrophotograph could also be incorporated into the final report to communicate clinically significant findings.

CLINICAL UTILITY OF THE BLOCK KEY

It is critical that the dissector records the site of origin of the submitted tissue blocks as this information may be important for pathologists who are reporting or reviewing the case. A detailed block key is, therefore, an integral part of histopathology reports, although often of little interest to the treating clinician and significantly lengthening the histopathology report. Block keys should, therefore, be brief and limited to information that is relevant for the case. Another option would be to develop a system wherein this information is entered into a separate field in the pathology electronic database that is excluded from the report issued to the clinical team. An abridged block key indicating the total number of blocks and identifying a relevant tumour block for further studies may be sufficient in the clinical report. However, a complete report including the detailed block key must accompany the slides provided to a reviewing pathologist.

A detailed block key is not necessary for simple specimens without focal lesions. It is sufficient to simply report the number of blocks taken to facilitate slide retrieval. It is also helpful to submit blocks from larger resection specimens in a standardised sequence.

MARGIN ASSESSMENT ISSUES

Accurate assessment of the margins of excision specimens is often critical as incomplete excision of a tumour or a close margin may be predictive of local recurrence and could trigger further surgical or non-surgical management. However, it is important to be aware of some significant issues around margin assessment.

Margin evaluation is based on a combination of macroscopic and microscopic examination. Great care should be taken when inking the surgical margins by ensuring that the tissue surface is blotted dry prior to inking, blotting the applied ink dry and then applying a mordant such as acetic acid or vinegar. This approach minimises ink tracking and permits more accurate interpretation of the margin status. Coloured gelatine could be superior to ink

for marking specimen margins because it is less messy and does not leach into the tissue.⁹

Specimen margin may not be resection margin

Pathologists assess the status of specimen margins, but these may not represent the true excision margin due to intraoperative or postoperative tissue disruption or manipulation. Tissue retraction following such disruption could result in false positive margins (figure 1). Often, the surgeon marks the true resection margin in the main specimen (with sutures or other markers) or sends the margins as separate specimens. In these situations, and whenever the location of the resection margins is known, inking the true resection margins with a different colour should be considered.

Tumour at ink may not be a positive specimen margin

It is common to ink the surface of excision specimens to facilitate microscopic assessment of margin status. However, ink may seep into the specimen, so an inked edge of a histological section may not represent the specimen margin. Cautery artefact may be a helpful (but not necessarily definitive) clue in some specimens as to whether an inked edge is a true margin. The converse is probably more important. If ink is not seen on the surface of a section from a block that includes the specimen margin, then the possibility of an incomplete plane of section should be considered and deeper levels or reorientation of the block undertaken.

Margin assessment is subject to inherent sampling error

Only a minute fraction (<0.2%) of the specimen margin will be histologically examined even if the specimen has been entirely embedded. As such, even if tumour is not seen at a specimen margin on the slides examined histologically, it is possible that there is margin involvement deeper in the tissue block (or in unsampled tissue).

Margin assessment is less reliable in ill-defined tumours

Most excision specimens are not completely submitted for histological assessment. Specimens are generally serially sliced, and a section (or a few sections) submitted from the area where the tumour appears closest to the margin macroscopically. Margin assessment is therefore more reliable in tumours that are macroscopically well-delineated (eg, invasive ductal carcinomas of the breast) than in more ill-defined tumours (eg, invasive lobular

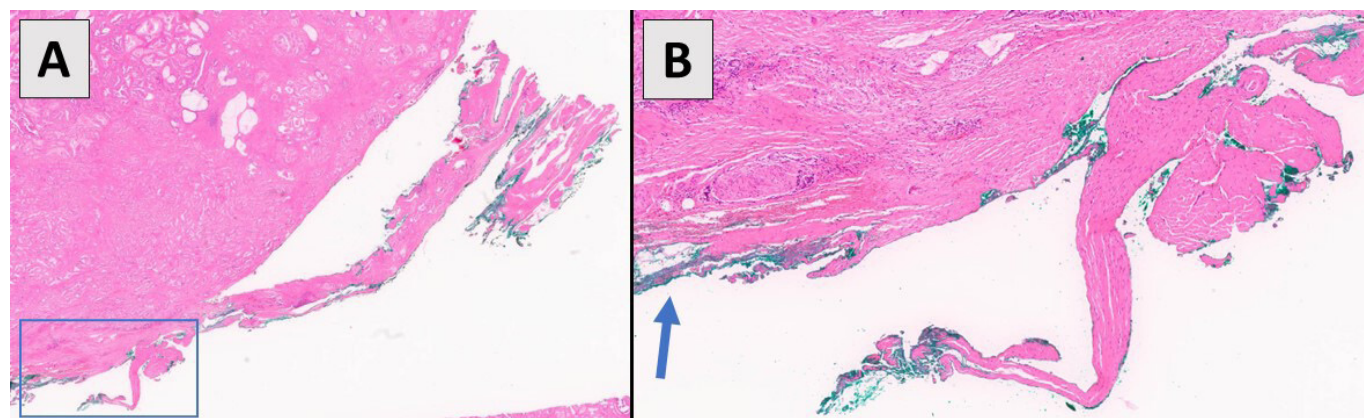


Figure 1 (A) Section of a robotic radical prostatectomy specimen showing irregular flaps of tissue on surface due to intraoperative tissue disruption. (B) Higher power of boxed area in A shows ink on specimen surface (arrow) that would not be the true resection margin. If the tissue flap is not represented in the examined plane of section then tumour at the inked specimen margin may be incorrectly interpreted as a positive excision margin.

carcinomas) where the closest specimen margin cannot be accurately identified by macroscopic examination. Margin assessment can also be difficult in postchemotherapy or radiotherapy resections where the residual tumour may not be macroscopically apparent.

Shave versus perpendicular sections of margins

Specimen margins can be evaluated with either shave sections taken parallel to the plane of the margin or sections perpendicular to this plane. The former would sample the entire margin but would not allow determination of the distance of the tumour from the margin. Shave margins can also be problematic in specimens where margin positivity is defined as tumour actually involving the specimen margin as tissue from the margin could be lost during trimming of the block. Perpendicular sections allow more precise measurements from tumour to margin but only a tiny fraction of the margin would be examined microscopically especially in larger specimens. Shave margins could be submitted when the gross tumour is well away from the margin and a perpendicular section taken in cases where the tumour is close to the margin to enable microscopic determination of the precise distance from the margin. However, the precise method of sampling margins often differs in different organ systems.

HISTOLOGICAL SAMPLING ISSUES

Judicious tissue sampling for histological examination is a critical part of macroscopic specimen assessment and pathology guidelines generally include recommendations on the number of blocks that should be submitted for microscopic assessment. These recommendations may be overly simplistic and there are some issues that merit further discussion.

How many blocks?

It is important to appreciate that only a minute percentage of the specimen is microscopically examined even when all the tissue is submitted. Since only a single 3–5 µm section is generally examined from each 3–5 mm thick tissue block, even complete submission of a resection specimen would result in histological examination of less than 0.2% of the specimen. Similarly, doubling the number of submitted blocks would result in histological examination of only an additional 0.1% of the specimen. Hence, pathologists should not be fixated on the number of blocks to be submitted from a specimen. The focus should

instead be on meticulous gross examination of thinly sliced specimens and ensuring that any macroscopically distinct areas are sampled. It is also important to carefully assess the peritoneal surface of gastrointestinal and gynaecological cancer specimens and sample any abnormal area identified.

The degree of macroscopic heterogeneity should be considered when deciding the extent of tissue sampling. Fewer blocks may be sufficient for tumours that are grossly homogeneous. However, there are some exceptions to this; for example, in endometrial carcinomas where the amount of lymphovascular space invasion is prognostically important in some tumours and greater sampling, particularly of the tumour–stroma interface, may identify more foci.

It is common for pathology guidelines to recommend submission of a certain number of tumour blocks per maximum tumour dimension. Such recommendations are ambiguous as it is unclear whether this refers to a block of tissue or a paraffin block. If two pieces of tissue are submitted in a single cassette, this would represent two tissue blocks in a single paraffin block (figure 2). The amount of tissue submitted in a cassette is not standardised so ‘blocks per cm of maximum tumour dimension’ can result in very variable tissue sampling. Greater clarity is necessary, particularly in the digital pathology era to preclude less tissue being submitted in each cassette to reduce file size.

A more appropriate recommendation in future guidelines may be ‘square cm of tissue per cm maximum tumour dimension’. An eyeball ‘guesstimate’ of the approximate tumour area submitted would suffice.

Sampling of ‘therapeutic’ resections

Some resections are performed as a ‘therapeutic’ procedure, often after the failure of conservative therapy. Examples of such specimens include hysterectomy for uterine prolapse, thyroidectomy for Graves’ disease, cosmetic breast reduction and transurethral resection of prostate (TURP). In these scenarios, histopathological assessment is of limited clinical value as the diagnosis has been established preoperatively.¹⁰ It is important to carefully examine these specimens macroscopically to identify any focal abnormalities that may prove to be clinically significant. However, routine sampling of macroscopically normal tissue has little clinical utility. Pathology guidelines recommend submission of up to seven blocks from a total thyroidectomy for Graves’ disease in which no focal abnormality has been identified.¹¹ Such sampling may be excessive as the diagnosis of Graves’ disease has been preoperatively established. Identification of incidental papillary ‘microcarcinoma’ is unlikely to be clinically significant, particularly after a total thyroidectomy, but could have significant psychological and financial consequences.¹²

Another example of tissue oversampling that could have significant adverse clinical consequences involves protocols for processing TURP specimens from patients with no clinical suspicion of prostate cancer. Current international guidelines require submission of about 11 blocks from a 25 gm TURP specimen.^{13 14} TURP is generally a therapeutic procedure performed to treat urinary retention that could not be satisfactorily managed by medical therapy. Very limited sampling would therefore be sufficient to detect prostate cancer that is large enough to cause urinary retention and more extensive sampling protocols are specifically designed to detect occult prostate cancer. The latter would, therefore, amount to histological screening for prostate cancer. It is important to note that in sharp contrast to prostate-specific antigen testing, patients have not been counselled about the risks of detecting incidental prostate cancer and hence




Figure 2 A single 2 cm² tissue block (A) could be processed as one (B), two (C) or four (D) paraffin blocks.

have not provided an informed consent for histological cancer screening. We therefore suggest re-evaluation of current TURP sampling protocols.

CONCLUSIONS

In this review, we have outlined some issues with current macroscopic examination of pathology specimens and have suggested some modifications. However, there are significant differences between healthcare systems globally and pathologists are required to conform to their national guidelines. These suggestions should, therefore, be considered and adapted as necessary to suit local requirements. We hope that this paper will engender debate and that the issues we raise will be discussed and addressed in future guidelines.

Handling editor Vikram Deshpande.

Twitter Murali Varma @MuraliV72899596, Runjan Chetty @runjanchetty and Yaileen D Guzmán-Arocho @guzmanarocho

Contributors MV wrote the first draft of the paper. All authors contributed to modifying and finalising the manuscript.

Funding The authors have not declared a specific grant for this research from any funding agency in the public, commercial or not-for-profit sectors.

Competing interests MV, LCC and RC are Associate Editors, Journal of Clinical Pathology.

Patient consent for publication Not applicable.

Provenance and peer review Commissioned; externally peer reviewed.

ORCID iDs

Murali Varma <http://orcid.org/0000-0003-1385-2045>

Laura C Collins <http://orcid.org/0000-0001-6751-4792>

Runjan Chetty <http://orcid.org/0000-0002-2124-515X>

Dipti M Karamchandani <http://orcid.org/0000-0002-0351-2859>

Monika Vyas <http://orcid.org/0000-0002-7020-9948>

Yaileen D Guzmán-Arocho <http://orcid.org/0009-0007-7574-2729>

Adam V Jones <http://orcid.org/0009-0009-9852-7348>

W Glenn McCluggage <http://orcid.org/0000-0001-9178-4370>

REFERENCES

- 1 Vyas M, Karamchandani D. Essentials of macroscopic evaluation of specimens from gastrointestinal tract. *J Clin Pathol* 2024;77:169–76.
- 2 Varma M, Dormer J. Macroscopy of specimens from the Genitourinary system. *J Clin Pathol* 2024;77:177–83.
- 3 Parra-Herran C, Talia KL, McCluggage WG. Macroscopic examination of gynaecological specimens: a critical and often Underemphasised aspect of pathological reporting. *J Clin Pathol* 2024;77:190–203.
- 4 Guzman Y, Collins LC. Pragmatic guide to the macroscopic evaluation of breast specimens. *J Clin Pathol* 2024;77:204–10.
- 5 Conn B, Pring M, Jones A. Macroscopy of specimens from the head and neck. *J Clin Pathol* 2024;77:185–9.
- 6 Amin MB, Edge S, Greene F, et al. *AJCC Cancer Staging Manual, 8th edn*. New York, NY: Springer Verlag, 2016.
- 7 Ellis IO, Al-Sam S, Anderson N, et al. Royal college of Pathologists UK. Pathology reporting of breast disease in surgical excision specimens incorporating the dataset for histological reporting of breast cancer. Available: <https://www.rcpath.org/profession/guidelines/cancer-datasets-and-tissue-pathways.html> [Accessed 18 Jun 2023].
- 8 Varma M, Morgan JM. The weight of the prostate gland is an excellent surrogate for gland volume. *Histopathology* 2010;57:55–8.
- 9 Armstrong JS, Weinzweig IP, Davies JD. Differential marking of excision planes in screened breast lesions by organically coloured gelatins. *J Clin Pathol* 1990;43:604–7.
- 10 Liebmann R, Varma M, Royal College of Pathologists UK. Best practice recommendations: histopathology and cytopathology of limited or no clinical value. Available: <https://www.rcpath.org/profession/guidelines/specialty-specific-publications.html> [Accessed 18 Jun 2023].
- 11 Royal College of Pathologists Australasia. Macroscopic cut-up manual: thyroid. Available: <https://www.rcpa.edu.au/Manuals/Macroscopic-Cut-Up-Manual/Endocrine/Thyroid> [Accessed 18 Jun 2023].
- 12 Shah V, Scott-Coombes D, Varma M. Cancer overdiagnosis: pathologists in the dock. *Arch Pathol Lab Med* 2019;143:781.
- 13 Oxley J, Varma M, Berney DM, et al. Dataset for histopathology reports for prostatic carcinoma. Available: <https://www.rcpath.org/profession/guidelines/cancer-datasets-and-tissue-pathways.html> [Accessed 18 Jun 2023].
- 14 Paner GP, Strigley JR, Pettus J, et al. College of American Pathologists. Protocol for the examination of TURP and Enucleation specimens from patients with carcinoma of the prostate gland. Available: http://www.cap.org/web/home/protocols-and-guidelines/cancer-reporting-tools/cancer-protocol-templates?_afLoop=47010688453105 [Accessed 18 Jun 2023].