




# Cystic neutrophilic granulomatous mastitis: sensitivity and specificity of 16s rRNA and Sanger sequencing for *Corynebacterium* spp

Ellen Yang,<sup>1</sup> Robert Kozak,<sup>2</sup> Sharon Nofech-Mozes,<sup>1,2</sup> Elsa Salvant <sup>3</sup>, Ekaterina Olkhov-Mitsel <sup>2</sup>, Elzbieta Slodkowska,<sup>1,2</sup> Anna Plotkin,<sup>1,2</sup> Wedad Hanna,<sup>1,2</sup> Fang-I Lu <sup>1,2</sup>

<sup>1</sup>Department of Laboratory Medicine and Pathobiology, University of Toronto, Toronto, Ontario, Canada

<sup>2</sup>Precision Diagnostics and Therapeutics Program (Laboratory Medicine), Sunnybrook Health Sciences Centre, Toronto, Ontario, Canada

<sup>3</sup>Sunnybrook Research Institute, Sunnybrook Health Sciences Centre, Toronto, Ontario, Canada

## Correspondence to

Dr Fang-I Lu, Department of Laboratory Medicine and Pathobiology, University of Toronto, Toronto M5S, Ontario, Canada; fangi.lu@sunnybrook.ca

Received 30 October 2022  
Accepted 9 January 2023  
Published Online First  
25 January 2023

## ABSTRACT

**Aims** Cystic neutrophilic granulomatous mastitis (CNGM) is a subtype of granulomatous mastitis (GM) associated with *Corynebacterium* spp infection. We aimed to analyse the prevalence of *Corynebacteria* in CNGM and non-CNGM cases.

**Methods** Breast specimens diagnosed as granulomatous inflammation between 2010 and 2020 were reviewed to identify a CNGM cohort and a non-CNGM cohort. Polymerase chain reaction-based identification of *Corynebacteria* by 16S ribosomal RNA (16S rRNA) primers, followed by confirmatory Sanger sequencing (SS), was performed on all cases. Clinical, radiological and microbiology data were retrieved from the electronic patient records.

**Results** Twenty-eight CNGM cases and 19 non-CNGM cases were identified. Compared with the non-CNGM cohort, patients in the CNGM cohort were more likely to be multiparous ( $p=0.01$ ), breast feeding ( $p=0.01$ ) and presenting with a larger breast mass ( $p<0.01$ ), spontaneous drainage ( $p=0.05$ ) and skin irritation ( $p<0.01$ ). No significant difference in the prevalence of *Corynebacteria* between the cohorts (7% vs 11%,  $p=0.68$ ) by microbiological culture was identified. Compared with microbiology culture, the sensitivity and specificity of each *Corynebacterial* detection method were 50% and 81% for Gram stain, and 25% and 100% for 16S rRNA combined with SS. Regardless of the diagnosis, patients positive for *Corynebacteria* were more likely to have a persistent disease ( $p<0.01$ ).

**Conclusion** CNGM presents as a large symptomatic breast mass in multiparous breastfeeding women. The importance of adequate sampling and repeated microbiology culture in conjunction with sequencing on all GM cases with persistent disease is paramount.

## INTRODUCTION

Cystic neutrophilic granulomatous mastitis (CNGM) is an uncommon subtype of granulomatous mastitis (GM), characterised by neutrophilic and lipogranulomatous inflammation surrounding cystic spaces or lipid vacuoles.<sup>1</sup> These spaces occasionally contain rod-shaped, Gram-positive bacilli, with the current literature suggesting *Corynebacterium* spp as the leading causative organism.<sup>1–3</sup> It was first described by Paviour *et al* as lipogranulomatous inflammation centred around coryneform bacteria, and a causal role of *Corynebacterium* was

## WHAT IS ALREADY KNOWN ON THIS TOPIC

⇒ Cystic neutrophilic granulomatous mastitis (CNGM) is more likely to occur in breastfeeding and multiparous women, and is thought to be associated with *Corynebacterial* infection.

## WHAT THIS STUDY ADDS

⇒ Histological findings of CNGM may not adequately predict *Corynebacterial* infection due to sampling issues. However, *Corynebacterial* infection is associated with worse clinical outcomes.

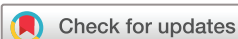## HOW THIS STUDY MIGHT AFFECT RESEARCH, PRACTICE OR POLICY

⇒ No optimal testing modality currently exists for the detection of *Corynebacterium*. Repeated microbiology culture in conjunction with sequencing should be considered in cases of persistent or recurrent granulomatous mastitis, regardless of the histological morphology.

postulated due to its deep location within the breast tissue, even though it has previously been known as normal skin flora.<sup>4</sup> Taylor *et al* also identified suppurative granulomas accompanied by Gram-positive bacilli, leading to the conclusion that *Corynebacterium* species had a strong association with GM.<sup>1</sup>

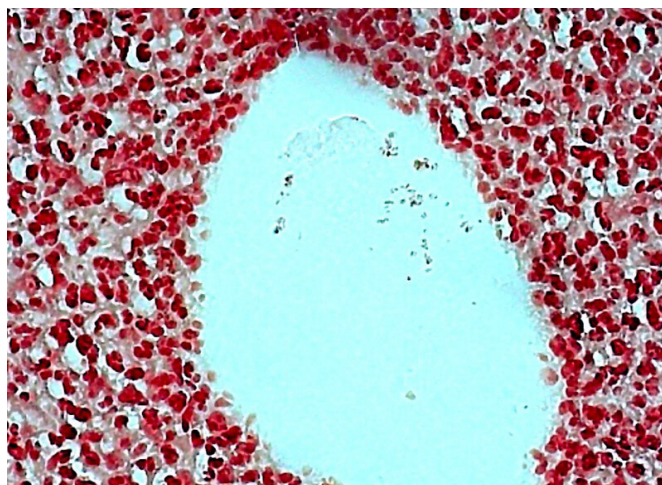
Clinically, CNGM often presents as a breast mass with nipple discharge, pain and erythema in women of reproductive age.<sup>2–4</sup> Both its clinical and radiological presentations can mimic and raise concern for invasive carcinoma. It has been associated with breast feeding in which the bacterium is postulated to gain entry via lactiferous ducts during lactation.<sup>1</sup> CNGM has a chronic debilitating course often requiring a prolonged course of treatment even after symptom cessation.<sup>2–4</sup> Management of CNGM is highly variable and often involves antibiotics with or without oral corticosteroids, and rarely surgical resection of breast mass.<sup>2–4</sup> Previous studies have shown its notable recurrence rate, ranging from 4% to 25%, especially in patients with a history of cigarette smoking and isolation of *Corynebacterium kroppenstedtii*.<sup>2–5</sup>

The definition of CNGM is still evolving and there are no universally accepted diagnostic criteria, especially given that *Corynebacterial* infection can



© Author(s) (or their employer(s)) 2024. No commercial re-use. See rights and permissions. Published by BMJ.

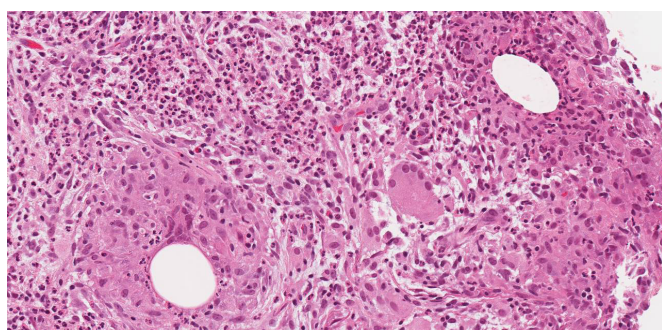
**To cite:** Yang E, Kozak R, Nofech-Mozes S, *et al*. *J Clin Pathol* 2024;**77**:306–311.



**Figure 2** Gram-stained slide of cystic neutrophilic granulomatous mastitis (x40 magnification). Rod-shaped, Gram-positive bacteria are identified in the cystic spaces.

be challenging to prove due to its fastidious nature by routine culture methods. As a result, the diagnosis of CNGM is often missed or delayed. Fujii *et al* suggested that the real-time PCR analysis using DNA templates extracted from formalin-fixed paraffin-embedded (FFPE) sections can be used to detect the *Corynebacterium* genome.<sup>6</sup> There has been inconsistent success with 16S ribosomal RNA (16S rRNA) sequencing as shown by Gautham *et al*.<sup>3</sup> Using a primer targeting the V5–V6 region that was thought to be conserved in *Corynebacterium* spp, the positivity rate in histologically diagnosed CNGM cases was found to be 52.2%.<sup>7</sup> However, existing literature has not examined and compared all available methods for *Corynebacterium* identification in terms of sensitivity and specificity and has inconsistently identified different methods as the reference standard of identification. In addition, current studies have not compared the clinicopathological findings of patients with features of CNGM with those with GM, but without features of CNGM. Tariq *et al* showed that 68.7% of granulomatous lobular mastitis (GLM) cases were positive for *C. kroppenstedtii* by 16S rRNA SYBR real-time PCR, but only 56.7% of GLM cases showed definitive histological features of CNGM.<sup>8</sup> The GLM group was compared with 10 cases of non-granulomatous abscess in the control group, which were negative for *C. kroppenstedtii* DNA.<sup>8</sup>

In this study, we examined the clinicopathological features of CNGM versus non-CNGM cases, including their association with *Corynebacteria*, and compared the sensitivity



**Figure 1** H&E-stained slide of cystic neutrophilic granulomatous mastitis (x20 magnification). Granulomatous inflammation surrounds cystic spaces/lipid vacuoles that are lined by neutrophils.

and specificity of the various identification methods for *Corynebacteria*.

## MATERIALS AND METHODS

A retrospective search of breast specimens with a diagnosis of granulomatous inflammation identified 82 cases from 2010 to 2020. Seventy-seven cases with available HE-stained slides were reviewed by two pathologists specialising in breast pathology and one anatomical pathology resident to reach a consensus on the histologically diagnosed CNGM cohort and non-CNGM cohort. The following histological features were examined: (1) granulomatous inflammation, (2) lipid vacuoles in the form of cystic spaces within the granulomatous inflammation and (3) neutrophils rimming the cystic spaces/lipid vacuoles. Rod-shaped, Gram-positive bacteria were occasionally identified within the cystic spaces/lipid vacuoles on HE-stained (and/or Gram-stained if available) slides, but were not required for the diagnosis CNGM. The case was categorised as CNGM when all three features were present and a consensus was reached by all reviewers (figures 1 and 2). The case was categorised as non-CNGM when one or two features were present. All cases that lacked all of the above histological features were excluded.

Areas diagnostic of CNGM were marked on HE-stained slides, and the circled areas were then microdissected from unstained 10 µm-thick FFPE tissue sections which were deparaffinised, dehydrated, air dried and then subjected to DNA extraction using the PinPoint slide DNA isolation system. DNA concentration was measured by the NanoDrop spectrophotometer (Thermo Fisher Scientific, Waltham, Massachusetts, USA). DNA was amplified by AmpliTaq Gold 360 (Thermo Fisher Scientific) on the Rotorgene RG 6000 (Corbet Research, Saffron Walden, UK), as per protocol in the Molecular Microbiology laboratory for 16S rRNA sequencing at Sunnybrook Health Sciences Centre. For each sample, PCR was performed in duplicate. Non-DNA template controls and *Corynebacterium* positive DNA controls were included in each run to monitor PCR contamination issues and confirm PCR positive samples. 16S rRNA sequencing was performed on all samples to facilitate bacterial identification.<sup>9</sup> PCR was performed using primers for the 16S intragenic region of the bacterial rRNA gene as has been described previously.<sup>10</sup> Following this, amplicons were purified and Sanger sequencing (SS) was performed to determine the bacterial species present using the following primers: 16S-F: AGA GTT TGA TCA TGG CTC AG; 16S-R: GGA CTA CCA GGG TAT CTA AT. Sequencing was performed on all samples where an amplicon was generated through the centre for Applied Genomics facility using dual ABI 3730XL instruments. The resulting sequences were queried in the GenBank database using BLASTn (accessed on June 2021). For this study, we considered the generation of any amplicon by the 16S PCR as a non-specific screening test for both cohorts prior to confirmatory SS.

Where bacterial culture was performed, the aspirate was planted on sheep blood agar enriched with 0.1% Tween 80, in addition to standard media, and incubated at 37°C. Bacterial identification was performed using matrix-associated laser desorption ionisation-time of flight (MALDI-TOF) mass spectrometry (MS).<sup>11</sup>

Clinical features including patient age, clinical presentation, gravida status, breastfeeding history, smoking history, a history of breast conditions, treatment modalities and recovery course,



all of which were retrieved from the electronic patient records, along with radiological features and microbiology workup results.

Statistical analysis was performed using SPSS V.26.0 (International Business Machines, Armonk, New York, USA).  $\chi^2$  test was used to calculate differences in the clinical presentation, treatment outcome and the prevalence of *Corynebacteria* between CNGM versus non-CNGM cohorts. Values of  $p < 0.05$  were considered statistically significant. Sensitivity and specificity were calculated using microbiology culture as the reference standard.

## RESULTS

Of 77 breast specimens with a diagnosis of granulomatous inflammation, 28 CNGM cases and 19 non-CNGM cases were identified. The CNGM cohort all, at least focally, demonstrated aggregates of multinucleated histiocytes surrounding cystic spaces/lipid vacuoles, with neutrophils rimming the periphery of the cystic spaces/lipid vacuoles, with or without the presence of rod-shaped Gram-positive bacteria within the cystic spaces/lipid vacuoles. The non-CNGM cohort demonstrated some but not all of these features, most commonly having only granulomatous inflammation with or without neutrophils and no cystic spaces/lipid vacuoles. The rest of the cases did not meet our preset diagnostic criteria for CNGM and non-CNGM and were excluded.

### Clinical presentations

The median age for CNGM was 39.5 years (ranging from 29 to 64 years). Most patients were multiparous (79%) and had a breastfeeding history (71%). Few had a smoking history (14%) and a history of breast conditions (21%), including a patient with previous invasive lobular carcinoma, 1 case of breast reduction, 2 cases with benign breast lesion resections, and 2 cases with previous bacterial mastitis. Most presented with a breast mass (93%) with size ranging from 1.6 to 14 cm, associated with pain (82%), spontaneous discharge (61%) and skin irritation (89%).

The median age for non-CNGM was 40 years (ranging from 24 to 77 years). Some patients were multiparous (47%) and had a breastfeeding history (47%). Forty-two per cent of the non-CNGM cohort had a previous breast condition, including 2 patients with invasive carcinoma status post resection and 6 patients with mastitis or breast abscess. Most presented with a breast mass (74%) with size ranging from 0.8 to 7.4 cm, associated with pain (74%), spontaneous discharge (32%) and skin irritation (37%).

The CNGM cohort was more likely to be multiparous ( $p = 0.01$ ) with a history of breast feeding ( $p = 0.01$ ), and presenting with a larger breast mass ( $p < 0.01$ ), spontaneous drainage ( $p = 0.05$ ) and skin irritation ( $p < 0.01$ ). There was no statistical difference in age, smoking history and presentation with a painful mass (table 1).

### Microbiology studies

Gram stain slides were available for review in 22 (79%) of CNGM and 11 (58%) of non-CNGM cases. Microbiology culture of fresh tissue was performed on 19 (68%) CNGM and 8 (42%) non-CNGM cases. 16S rRNA of FFPE tissue were done on all CNGM and non-CNGM cases, with SS performed on the 7 CNGM and 10 non-CNGM with a positive 16S rRNA result (table 1).

Out of 5 CNGM cases with a positive microbiology culture and/or sequencing for any bacterium, 2 CNGM cases

**Table 1** Comparison between cystic neutrophilic granulomatous mastitis (CNGM) and non-CNGM (non-CNGM) cohorts

	CNGM	Non-CNGM	P value
<b>Cases</b>	28	19	
<b>Clinical features</b>			
Mean age (years)	39.5	40	0.70
Multiparity	22 (79%)	9 (47%)	0.01
Breast feeding	20 (71%)	9 (47%)	0.01
Smoking	4 (14%)	6 (32%)	0.16
Mass	26 (93%)	14 (74%)	0.13
Size (cm)	6.4	3.2	<0.01
Pain	23 (82%)	14 (74%)	0.34
Spontaneous drainage	17 (61%)	6 (32%)	0.05
Skin irritation	25 (89%)	7 (37%)	<0.01
<b>Microbiology</b>			
Gram stain performed	22 (79%)	11 (58%)	
+ve Ggram stain	6 (27%)	1 (9%)	0.23
Culture performed	19 (68%)	8 (42%)	
+ve culture	4 (21%)	4 (50%)	0.11
+ve corynebacterial culture	2 (11%)	2 (25%)	0.68
16S rRNA performed	28 (100%)	19 (100%)	
+ve 16S rRNA	7 (25%)	10 (53%)	0.01
SS performed	7 (25%)	10 (53%)	
+ve SS for any bacterium	2 (29%)	5 (50%)	0.04
+ve Corynebacterial SS	1 (14%)	0	0.44
<b>Treatment</b>			
Antibiotics	21 (75%)	9 (47%)	0.03
Drainage	5 (18%)	5 (26%)	0.51
Excision	0	1 (5%)	0.23
<b>Outcome</b>			
Resolution	14 (50%)	16 (84%)	0.10
Recurrence	3 (11%)	0	0.14
16S rRNA, 16S ribosomal RNA; SS, Sanger sequencing; +ve, positive.			

were positive for *Corynebacteria* by microbiology culture (cases 1 and 2). SS failed to identify *Corynebacteria* in 1 of the 2 Corynebacterial culture-positive cases. The non-Corynebacterial organisms identified included *Sphingomonas echinoides* (case 3), *Mycobacterium abscessus* (case 4) and *Staphylococcus lugdunensis* (case 5). On histological examination, 6 cases (27% of cases with Gram stain) demonstrated Gram-positive organisms, including all cases positive for *Corynebacterium* (table 2).

Two non-CNGM cases were positive for *Corynebacteria* by microbiology culture (cases 2 and 3) out of 8 non-CNGM cases with a positive microbiology culture and/or sequencing for any bacterium. SS failed to identify both Corynebacterial culture-positive cases. The non-Corynebacterial organisms identified included *Prevotella* spp, *Peptoniphilus asaccharolyticus* and *Atopobium minutum* (case 1), *Peptostreptococcus anaerobius* and *Dicentra* spp (case 4), *Staphylococcus saccharolyticus* (case 5), *Peptoniphilus harei* (case 6), *Bacillus* spp (case 7) and *Sphingomonas* spp (case 8). On histological examination, 1 case (9% of cases with Gram stain) demonstrated Gram-positive organisms; none of the cases positive for *Corynebacterium* demonstrated Gram-positivity (table 3).

The prevalence of *Corynebacteria* was not significantly different between these cohorts by microbiological culture ( $p = 0.68$ ) or by SS ( $p = 0.44$ ). However, the non-CNGM cohort had more bacteria (including *Corynebacterium*

**Table 2** Clinical, radiological and pathological features of cystic neutrophilic granulomatous mastitis (CNGM) cohort with positive microbiological studies

Case	1	2	3	4	5
<b>Clinical features</b>					
Age (years)	40	33	44	37	49
Gravida	G2P1	G3P1	G3P3	G1P1	G5P3
Breast feeding	Unknown	Y	Y	Y	Y
Mass	Y (unifocal)	Y (unifocal)	Y (multifocal)	Y (unifocal)	Y (multifocal)
Size (cm)	6.5	7.7	4	10	3
Pain	Y	Y	Y	Y	Y
Spontaneous drainage	Y	Y	Y	Y	Y
Skin irritation	N	Y	Y	Y	Y
<b>Microbiology</b>					
Gram stain	+	+	+	–	–
Culture	+ ( <i>Corynebacterium</i> spp)	+ ( <i>Corynebacterium</i> spp)	–	+ (non- <i>Corynebacterial</i> organ-isms)	+ (non- <i>Corynebacterial</i> organisms)
16S rRNA	+	+	+	–	+
SS	+ (Uncultured bacterium)	+ ( <i>Corynebacterium</i> spp)	+ (non- <i>Corynebacterial</i> organ-isms)	–	+ (Uncultured bacterium)
<b>Treatment</b>					
Antibiotics	Clavulin, Doxycycline	Cefalexin	None	Cefalexin, clindamycin, vancomycin, doxycycline	Cefalexin, cloxacillin
Steroids	N	N	N	N	N
Drainage	Y	N	N	N	Y
Excision	N	N	N	N	N
<b>Outcomes</b>					
Resolution	Y	Y	N	Y	N/A
Recurrence	Y (contralateral)	Y (ipsilateral)	N	N	N
Interval (months)	24	6	N/A	N/A	N/A
Culture	+ ( <i>Corynebacterium</i> spp)	–	Not done	Not done	Not done

+, positive; –, negative; N, no; N/A, information not available; 16S rRNA, 16S ribosomal RNA; SS, Sanger sequencing; Y, yes.

and non-*Corynebacterium*) than the CNGM cohort by SS ( $p=0.04$ ).

The rate of a positive result for the various detection methods was 21% (7/33) for Gram stain, 36% (17/47) for 16S rRNA alone, 41% (7/17) for 16S rRNA followed by SS, and 30% (8/27) for

microbiology culture for any culturable bacteria (table 1). Using *Corynebacterial* microbiology culture as the reference standard, the sensitivity and specificity of *Corynebacterial* detection by each method were 50% and 81% for Gram stain, and 25% and 100% for 16S rRNA combined with SS (table 4).

**Table 3** Clinical, radiological and pathological features of non-cystic neutrophilic granulomatous mastitis/granulomatous mastitis (non-CNGM) cohort with positive microbiological studies

Case	1	2	3	4	5	6	7	8
<b>Clinical features</b>								
Age (years)	25–29	30–34	40–44	30–34	45–49	30–34	30–34	40–44
Gravida	G0P0	G2P2	G2P1	G2P2	G3P2	G3P2A1	G1P1	N/A
Breast feeding	N	Y	N/A	Y	Y	Y	Y	N/A
Mass	Y (unifocal)	Y (multifocal)	Y (multifocal)	Y (multifocal)	Y (unifocal)	Y (unifocal)	N	N/A
Size (cm)	2.0	6.4	3.8	1.5	1.2	0.8	N/A	N/A
Pain	Y	Y	Y	Y	N	Y	N	N/A
Spontaneous drainage	Y	Y	Y	N	N	N	N	N/A
Skin irritation	Y	Y	Y	N	N	Y	N	N/A
<b>Microbiology</b>								
Gram stain	Not done	–	–	–	–	–	Not done	–
Culture	+ (non- <i>Corynebacterial</i> organisms)	+ ( <i>Corynebacterium</i> spp)	+ ( <i>Corynebacterium</i> spp)	+ (non- <i>Corynebacterial</i> organisms)	Not done	Not done	Not done	Not done
16S rRNA	+	+	+	+	+	+	+	+
SS	+ (Uncultured bacterium)	–	+ (Uncultured bacterium)	+ (non- <i>Corynebacterial</i> organisms)	+ (non- <i>Corynebacterial</i> organisms)	+ (non- <i>Corynebacterial</i> organisms)	+ (non- <i>Corynebacterial</i> organisms)	+ (non- <i>Corynebacterial</i> organisms)
<b>Treatment</b>								
Antibiotics	Cefalexin, trimethoprim/sulfamethoxazole	Clindamycin, cefalexin, ceftriaxone	Clavulin, doxycycline	Clavulin	N	Y	N	N/A
Steroids	N	N	N	N	N	N	N	N/A
Drainage	Y	Y	Y	N	N	N	N	N/A
Excision	N	N	N	N	N	N	N	N/A
<b>Outcomes</b>								
Resolution	Y	Y	N	Y	Y	Y	N/A	N/A
Recurrence	N	N	N	N	N	N	N/A	N/A

–, negative; +, positive; N, no; N/A, not available; 16S rRNA, 16S ribosomal RNA; SS, Sanger sequencing; Y, yes.

**Table 4** Sensitivity and specificity of identification methods for *Corynebacterium* spp (using corynebacterial culture positivity as a reference standard)

	Sensitivity	Specificity
Gram stain	50%	81%
16S rRNA followed by SS	25%	100%
16S rRNA, 16S ribosomal RNA; SS, Sanger sequencing.		

### Treatment and outcome

For the CNGM cohort, 21 patients (75%) received antibiotic treatment, with 12 patients (43%) receiving more than 1 type of antibiotics. Six patients (21%) also received concurrent corticosteroids. The most frequently prescribed antibiotic was cefalexin (48%), followed by doxycycline (33%). Therapeutic drainage was performed in 5 cases (18%). Complete resolution was achieved in 13 patients (46%), taking 4.6 months on average. Three patients (10%) had a recurrence in the ipsilateral or contralateral breast, with a mean time-to-recurrence of 13 months (table 2).

For the non-CNGM cohort, 9 patients (47%) received antibiotic treatment, with 4 patients (21%) receiving more than 1 type of antibiotics; no patients received concurrent corticosteroids. The most frequently prescribed antibiotic was clavulin (44%), followed by cefalexin (33%). Therapeutic drainage was performed in 5 patients (26%). Complete resolution was achieved in 16 patients (84%), taking 11.2 months on average. No patient had a recurrence in the ipsilateral or contralateral breast (table 3).

There was no statistical significance between the CNGM and non-CNGM cohorts for complete resolution ( $p=0.10$ ) and recurrence ( $p=0.14$ ). However, regardless of the histological diagnosis, patients positive for *Corynebacteria* were more likely to have a persistent disease with less complete resolution ( $p<0.01$ ), although they were not significantly more likely to recur ( $p=0.12$ ) (table 5).

### DISCUSSION

There is a significant overlap in morphology between CNGM and other forms of GM. A stepwise assessment of granulomatous inflammation of the breast has been proposed, in which histological features, Gram stain and microbiological studies are combined to improve diagnostic certainty.<sup>5</sup> However, our study suggests that the distinctions between CNGM and other forms of GM may be clinically irrelevant. While the CNGM cohort was significantly more likely to be breast feeding and multiparous than the non-CNGM cohort, and to present with symptomatic mastitis including larger breast mass, spontaneous nipple discharge and skin irritation, there were no significant differences in the rate of *Corynebacteria* positivity or clinical outcomes between these two cohorts. Instead, poor clinical outcomes were associated with *Corynebacterial* infection, highlighting the importance of adequate sampling and microbiology

**Table 5** Outcomes of *Corynebacteria*-positive versus *Corynebacteria*-negative cases

Corynebacterial infection	Corynebacterium spp +ve	Corynebacterium spp -ve	P value
Cases	4	43	
Resolution	1 (25%)	33 (77%)	<0.01
Recurrence	1 (25%)	1 (2%)	0.12
+ve, positive; -ve, negative.			

studies on cases initially diagnosed as non-CNGM but with persistent disease, in order not to miss the organisms and to initiate the appropriate treatment.

Due to the retrospective nature of the study, not all histological Gram stain and/or microbiology culture were available for review. The limited tissue remaining in the tissue block also prevented retrospective examination. Future prospective studies using all available testing modalities (culture, 16S rRNA sequencing) should be considered, as the awareness and clinical suspicion for CNGM may be raised at the time of clinical examination. Though some of the Gram stain data are missing, the percentage of cases with Gram stain performed is relatively similar between the CNGM and non-CNGM cohorts—79% (22/28) in the CNGM group, and 58% (11/19) in the non-CNGM group (table 1). In addition, our study was the first to compare the sensitivity and specificity of Gram stain vs 16S rRNA and SS to detect *Corynebacteria*, using microbiology culture as the reference standard, based on cases that had both Gram stain and SS results available. Although 16S rRNA combined with SS outperformed Gram stain as the more specific (100%) detection method, its sensitivity was only 25%, limiting its routine use for the diagnosis of *Corynebacterial* infection. Overall, our findings suggest that, when there is strong clinical suspicion for an infectious aetiology, 16S rRNA combined with SS, in conjunction with culture, should be considered regardless of Gram stain results.

Current literature agrees that microbiological evidence of *Corynebacterium* species and/or histochemical identification is challenging. The fastidious nature of these bacteria is explained by their lipophilic cell membrane lacking mycolic acids.<sup>8 12</sup> There are several alternative methods of identifying *Corynebacteria* to improve diagnostic certainty. These include the nanopore sequencing method, MALDI-TOF MS and 16S rRNA and *rpoB* gene sequence amplification with PCR.<sup>12–16</sup> Furthermore, our study identified several non-*Corynebacterial* organisms by microbiology culture and/or SS. Many of these organisms caused a false-positive 16S rRNA result, highlighting the need for a more specific PCR probe than 16S rRNA. Some organisms, such as *Sphingomonas* spp, *Peptoniphilus harei* and *Staphylococcus saccharolyticus*, were likely environment or skin contaminants that were acquired during sample collection. Unfortunately, a common and unavoidable problem working with FFPE tissue is the non-sterile handling of the specimen blocks. It is imperative that the interpretation of the histology, Gram stain, culture and sequencing results should be made in the correct clinical context. In addition, given that the current literature mostly associated *Corynebacterium* with CNGM, we only performed 16S rRNA followed by confirmatory SS with the aim of detecting *Corynebacterium*. However, our sequencing results identified several non-*Corynebacterial* organisms within the same patient, suggesting that CNGM may in-deed be associated with a polymicrobial population. Novel techniques using metagenomic sequencing have demonstrated potential in identifying *C. krop-penstedtii* from cases of GLM and has shown greater sensitivity than traditional culture methods.<sup>16 17</sup> Metagenomic sequencing has advantages over 16S rRNA sequencing methods in that it can detect a greater range of pathogens present in a sample, and often provide better identification of the microorganism. However, the high cost and technical sophistication has limited its wide scale application. Nonetheless, metagenomic sequencing offers promise as a future tool for investigating CNGM cases.

Empirical antimicrobial therapies are frequently the initial treatment option to cover for *Staphylococcus* spp as a conventional cause of mastitis. Because of their lipophilic nature,

lipophilic antibiotics including doxycycline, trimethoprim-sulfamethoxazole, clarithromycin and rifampicin are proposed to be more effective against *Corynebacteria* with the presence of lipogranulomas.<sup>11</sup> Susceptibility to rifampin, tetracycline, trimethoprim-sulfamethoxazole, linezolid and vancomycin was found in a study of 11 breast tissue and aspirate specimens that grew *C. kroppenstedtii* in culture.<sup>18</sup> Although the use of steroids was initially proposed for the treatment of GM and its association with autoimmune disease, treatment with steroids alone or in combination with antibiotics has also been used for CNGM.<sup>5, 18</sup> The lack of standardised treatment proves to add to the challenges of determining the effectiveness of each treatment's modalities. Our study highlighted the need for studies on larger samples to elucidate the optimal therapeutic regimens for CNGM.

## CONCLUSIONS

In our study, patients with CNGM were more likely to be breast feeding and multiparous, and to present with a symptomatic breast mass than patients with GM/non-CNGM. *Corynebacterium* spp were detected in 7% of CNGM and 11% of non-CNGM cases and their presence was associated with worse clinical outcomes regardless of the histological diagnosis, highlighting the importance of adequate sampling and microbiology studies on all GM cases with persistent disease. The clinical significance of organisms other than *Corynebacterium* spp in CNGM and the optimal therapeutic regimen for CNGM remains uncertain. However, it was discovered that using microbiology culture as the reference standard, 16S rRNA followed by SS was the most specific detection method for *Corynebacterium* spp, although the low sensitivity of this testing method limits its routine use.

**Handling editor** Vikram Deshpande.

**Contributors** All authors contributed to this study, including conception and design (EY, RK, SN-M, ES, AP, WH and F-IL), study conduct (EY, RK, SN-M, ES, EO-M, F-IL), data analysis (EY, RK, F-IL) and manuscript write-up (EY, RK, ES, SN-M, ES, AP, WH and F-IL). Dr Fang-I Lu accepts full responsibility for the work, conduct and publication of the study and have access to the research data.

**Funding** The authors have not declared a specific grant for this research from any funding agency in the public, commercial or not-for-profit sectors.

**Competing interests** None declared.

**Patient consent for publication** Not applicable.

**Ethics approval** The study was approved by the Research Ethics Board of Sunnybrook Health Sciences Centre, Toronto, Canada.

**Provenance and peer review** Not commissioned; externally peer reviewed.

**Data availability statement** All data relevant to the study are included in the article or uploaded as supplementary information.

## ORCID iDs

Elsa Salvant <http://orcid.org/0000-0002-5650-4748>

Ekaterina Olkhov-Mitsel <http://orcid.org/0000-0001-7945-7801>

Fang-I Lu <http://orcid.org/0000-0002-6414-7613>

## REFERENCES

- 1 Taylor GB, Paviour SD, Musaad S, et al. A clinicopathological review of 34 cases of inflammatory breast disease showing an association between corynebacteria infection and granulomatous mastitis. *Pathology* 2003;35:109–19.
- 2 Co M, Cheng VCC, Wei J, et al. Idiopathic granulomatous mastitis: a 10-year study from a multicentre clinical database. *Pathology* 2018;50:742–7.
- 3 Gautham I, Radford DM, Kovacs CS, et al. Cystic neutrophilic granulomatous mastitis: the Cleveland clinic experience with diagnosis and management. *Breast J* 2019;25:80–5.
- 4 Tan QT, Tay SP, Gudi MA, et al. Granulomatous mastitis and factors associated with recurrence: an 11-year single-centre study of 113 patients in Singapore. *World J Surg* 2019;43:1737–45.
- 5 Wu JM, Turashvili G. Cystic neutrophilic granulomatous mastitis: an update. *J Clin Pathol* 2020;73:445–53.
- 6 Fujii M, Mizutani Y, Sakuma T, et al. *Corynebacterium kroppenstedtii* in granulomatous mastitis: analysis of formalin-fixed, paraffin-embedded biopsy specimens by immunostaining using low-specificity bacterial antisera and real-time polymerase chain reaction. *Pathol Int* 2018;68:409–18.
- 7 Naik MA, Korlimarla A, Shetty ST, et al. Cystic neutrophilic granulomatous mastitis: a clinicopathological study with 16S rRNA sequencing for the detection of corynebacteria in formalin-fixed paraffin-embedded tissue. *Int J Surg Pathol* 2020;28:371–81.
- 8 Tariq H, Menon PD, Fan H, et al. Detection of corynebacterium kroppenstedtii in granulomatous lobular mastitis using real-time polymerase chain reaction and sanger sequencing on formalin-fixed, paraffin-embedded tissues. *Arch Pathol Lab Med* 2022;146:749–54.
- 9 Church DL, Cerutti L, Gürtler A, et al. Performance and application of 16S rRNA gene cycle sequencing for routine identification of bacteria in the clinical microbiology laboratory. *Clin Microbiol Rev* 2020;33:e00053–19.
- 10 Louie L, Goodfellow J, Mathieu P, et al. Rapid detection of methicillin-resistant staphylococci from blood culture bottles by using a multiplex PCR assay. *J Clin Microbiol* 2002;40:2786–90.
- 11 Tan C, Lu F-I, Aftanas P, et al. Whole genome sequence of corynebacterium kroppenstedtii isolated from a case of recurrent granulomatous mastitis. *IDCases* 2021;23:e01034.
- 12 Paviour S, Musaad S, Roberts S, et al. *Corynebacterium* species isolated from patients with mastitis. *Clin Infect Dis* 2002;35:1434–40.
- 13 Tauch A, Fernández-Natal I, Soriano F. A microbiological and clinical review on corynebacterium kroppenstedtii. *Int J Infect Dis* 2016;48:33–9.
- 14 Bao R, Gao X, Hu B, et al. Matrix-assisted laser desorption ionization time-of-flight mass spectrometry: a powerful tool for identification of corynebacterium species. *J Thorac Dis* 2017;9:3239–45.
- 15 Zasada AA, Mosiej E. Contemporary microbiology and identification of corynebacteria spp. Causing infections in human. *Lett Appl Microbiol* 2018;66:472–83.
- 16 Li X-Q, Yuan J-P, Fu A-S, et al. New insights of corynebacterium kroppenstedtii in granulomatous lobular mastitis based on nanopore sequencing. *J Invest Surg* 2022;35:639–46.
- 17 Bi J, Li Z, Lin X, et al. Etiology of granulomatous lobular mastitis based on metagenomic next-generation sequencing. *Int J Infect Dis* 2021;113:243–50.
- 18 Dobinson HC, Anderson TP, Chambers ST, et al. Antimicrobial treatment options for granulomatous mastitis caused by corynebacterium species. *J Clin Microbiol* 2015;53:2895–9.