

## CORRESPONDENCE

## The precious cell block

We describe a method for preparing a cell block from a very sparsely cellular cytology fluid sample. The aim is to ensure that cells are not lost during processing. We developed this method to perform immunohistochemistry on circulating tumour cells (CTC) extracted from the blood of patients with metastatic carcinoma, in which there are typically less than 20 cells in a 10 mL blood sample. The method could also be applicable to other sparsely cellular samples such as cerebrospinal fluid (CSF) samples, or eye vitreous fluid samples.

First, the cells are concentrated into a 90  $\mu$ L volume of fluid. In the case of CTCs this is obtained from a phosphate buffered saline backwash of a Parsortix CTC blood filter cassette (figure 1A–C; arrows mark CTCs). This filter cassette separates cells

based on their size and deformability. Circulating carcinoma cells, and cells from other non-haematological neoplasms, tend to be larger and more rigid than other blood cells. The concentrate could also be from centrifugation of a CSF sample, vitreous humour or similar, with removal of most of the supernatant and resuspension.

Next, a 40  $\mu$ L droplet of plasma or serum is placed at the centre of a clean glass microscope slide (figure 1D). In the case of CTCs, the plasma is derived from the patient's own blood sample, but fetal calf serum could be an alternative. A 12mm Cytofoam Disc is placed on top of the droplet on the slide and the 90  $\mu$ L sample containing the cells is added to the centre of the top face of the disc (figure 1E). A further 40  $\mu$ L of plasma or serum is then added (figure 1F). The surface of the disc is then prodded with a micropipette tip 30 times to encourage mixing of the fluids. A 500 mL plastic histology specimen container, or similar, is then prepared with a folded paper

towel across its floor that is soaked with 5 mL of neutral buffered formalin. The glass slide is then placed flat on top of this with the Cytofoam Disc uppermost (figure 1G). The container's lid is closed and left at room temperature for 24 hours for the sample to fix in the formalin vapour. The slide is then removed from the container and Cytofoam Disc prised from the surface of the glass slide with the edge of a scalpel. The disc is then wrapped in tissue paper and paraffin processed as for a biopsy specimen. The discs are 2mm thick in the unprocessed state, but less thick when processed, and sometimes slightly concave or convex. We are reliably able to cut 50–80 paraffin full face sections, 3  $\mu$ m thick, from each cell block and place five sections on each standard histology slide. In this way, we are able to perform immunostains for at least 10 antibodies, to attempt to characterise the cells of interest. Having five sections on each slide (figure 1H) increases the number of cells that are seen for each immunostain. It might be possible to use gelatin foam (eg, Gelfoam) as a substitute for CytoFoam.

This technique allows routine H&E paraffin sections and immunohistochemistry to be used to characterise very sparsely cellular samples, and so makes it possible to analyse CTCs using the routine methods employed in most diagnostic histopathology laboratories. In the blood of some patients with metastatic carcinoma, CTCs can be recognised on immunohistochemistry (figure 1I), and some of these patients also have prominent circulating megakaryocytes (figure 1J).

It should be emphasised that the application of this method to the recognition and characterisation of CTCs in blood is not currently at a stage where it could be used in routine clinical practice. We are conducting a study of 50 patients with known, or suspected, metastatic carcinoma to assess the potential diagnostic utility of this method.

Frederick George Mayall,<sup>1</sup>  
Ian Bodger,<sup>1</sup> Justin Pepperell,<sup>2</sup> Lara Stevanato,<sup>3</sup>  
Arianna Hustler,<sup>3</sup> Kyra Mhairi Mumford<sup>3</sup>

<sup>1</sup>Department of Cellular Pathology, Musgrove Park Hospital, Taunton, UK


<sup>2</sup>Department of Respiratory Medicine, Musgrove Park Hospital, Taunton, UK

<sup>3</sup>Research and Development, ANGLE Europe Ltd, Guildford, UK

**Correspondence to** Dr Frederick George Mayall, Department of Cellular Pathology, Musgrove Park Hospital, Taunton TA1 5DA, UK; DrMayall@me.com

**Handling editor** Runjan Chetty.

**Contributors** The authors agree that they have all made substantial contributions to the conception or design of the work, or the acquisition, analysis



**Figure 1** A montage demonstrating the Parsortix blood filter technology (A–C), the cell block preparation method (D–G) and the resultant histological and immunohistochemical sections (H–J).

or interpretation of data; have been involved in drafting the work or revising it critically for important intellectual content; have/will have final approval of the version published; and agree to be accountable for all aspects of the work in ensuring that questions related to the accuracy or integrity of any part of the work are appropriately investigated and resolved.

**Funding** This work was funded by ANGLE Europe Ltd (commercial funding), IRAS Project ID: 209687.

**Competing interests** Taunton and Somerset NHS Foundation Trust employs FGM and JP, and contracts the services of IB. It has received funding from ANGLE Europe Ltd to support this work. ANGLE Europe Ltd employs LS, AH and KMM and is a subsidiary of Angle PLC, the owner of the Parsortix filter technology. The authors have no other competing interests to declare.

**Patient consent** Not required.

**Ethics approval** South Birmingham Research Ethics Committee (16/WM/0418).

**Provenance and peer review** Not commissioned; internally peer reviewed.

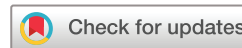

## OPEN ACCESS

**Open Access** This is an Open Access article distributed in accordance with the Creative Commons Attribution Non Commercial (CC BY-NC 4.0) license, which permits others to distribute, remix, adapt, build upon this work non-commercially, and license their derivative works on different terms, provided the original work is properly

cited and the use is non-commercial. See: <http://creativecommons.org/licenses/by-nc/4.0/>

© Article author(s) (or their employer(s) unless otherwise stated in the text of the article) 2018. All rights reserved. No commercial use is permitted unless otherwise expressly granted.



**To cite** Mayall FG, Bodger I, Pepperell J, et al. *J Clin Pathol* Epub ahead of print: [please include Day Month Year]. doi:10.1136/jclinpath-2018-205151

Received 12 March 2018

Revised 15 March 2018

Accepted 16 March 2018

*J Clin Pathol* 2018;**0**:1–2.  
doi:10.1136/jclinpath-2018-205151